

Afsheen Tabassum
Gert J. Meijer
X. Frank Walboomers
John A. Jansen

Evaluation of primary and secondary stability of titanium implants using different surgical techniques

Authors' affiliations:

Afsheen Tabassum, X. Frank Walboomers, John A. Jansen, Department of Biomaterials, Radboud University Nijmegen Medical Centre, Nijmegen, The Netherlands

Gert J. Meijer, Department of Implantology & Periodontology, Radboud University Nijmegen Medical Centre, Nijmegen, The Netherlands

Gert J. Meijer, Department of Oral and Maxillofacial Surgery, Radboud University Nijmegen Medical Centre, Nijmegen, The Netherlands

Corresponding author:

John A. Jansen, DDS, PhD
Department of Biomaterials, Dentistry
Radboud University Nijmegen Medical Centre
PO Box 9101
6500 HB Nijmegen, The Netherlands
Tel.: +31 24 3614920
Fax: +31 24 3614657
e-mail: j.jansen@dent.umcn.nl

Key words: bone healing, insertion torque, primary stability, removal torque, secondary stability, titanium implants, undersized surgical technique

Abstract

Objective: To investigate the influence of different surgical techniques on the primary and secondary implant stability using trabecular bone of goats as an implantation model.

Material and methods: In the iliac crest of eight goats, 48 cylindrical-screw-type implants with a diameter of 4.2 mm (Dyna[®]; Bergen op Zoom, the Netherlands) were installed, using three different surgical techniques: (i) 5% undersized, using a final drill diameter of 4 mm; (ii) 15% undersized, using a final drill diameter of 3.6 mm; and (iii) 25% undersized, using a final drill diameter of 3.2 mm. Peak insertion torque values were measured by a Digital[®] (MARK-10 Corporation, New York, NY, USA) torque gauge instrument during placement. At 3 weeks after implantation, removal torque was measured. Histomorphometrically, the peri-implant bone volume was measured in three zones; the inner zone (0–500 µm), the middle zone (500–1000 µm) and the outer zone (1000–1500 µm).

Results: Evaluation of the obtained data demonstrated no statistically significant difference between different surgical techniques regarding removal torque values. With respect to the percentage peri-implant bone volume (%BV), also no significant difference could be observed between all three applied surgical techniques for both the inner, middle and outer zone. However, irrespective of the surgical technique, it was noticed that the %BV was significantly higher for the inner zone as compared to middle and outer zone ($P < 0.05$) around the implant.

Conclusion: At 3 weeks after implant installation, independent of the used undersized surgical technique, the %BV in the inner zone (0–500 µm) peri-implant area was improved due to both condensation of the surrounding bone as also the translocation of host bone particles along the implant surface. Surprisingly, no mechanical beneficial effect of the 25% undersized surgical technique could be observed as compared to the 5% or 15% undersized surgical technique to improve primary or secondary implant stability.

One of the prerequisites to achieve optimal osseous fixation is primary implant stability at the time of surgery (LioubavinaHack et al. 2006; Tabassum et al. 2009, 2010a). Primary stability relies on the mechanical contact (friction) between implant and host bone and can be valued as the force that is required to place the implant into the host bone. After the installation of titanium implant, the primary stability decreases, due to a sequence of cellular and extracellular healing events taking place at the bone-implant interface (Fini et al. 2004). After peri-implant healing has started with blood clot formation, osteogenic cells deposit calcified matrix, which is followed by the formation of new woven and reparative trabecular bone (Mavrogenis et al. 2009). This early trabecular bone formation provides biological fixation to the implant

(Berglundh et al. 2003). Thus, primary mechanical stability is gradually replaced with secondary biological stability provided by newly formed bone as osseointegration occurs during early wound healing (Raghavendra et al. 2005; Atsumi et al. 2007).

Several factors that influence both primary and secondary implant stability have been elucidated in various animal and clinical studies, such as

(i) Surgical technique for implant placement (Albrektsson 2001; Tabassum et al. 2010a,b); (ii) patient bone quality and quantity (Sevimay et al. 2005); (iii) implant surface characteristics (mainly surface roughness and chemistry, de Jonge et al. 2008; Tabassum et al. 2011b, 2012); and (iv) implant design (O'Sullivan et al. 2000, 2004; Lee et al. 2005).

Date:
Accepted 30 March 2013

To cite this article:

Tabassum A, Meijer GJ, Walboomers XF, Jansen JA. Evaluation of primary and secondary stability of titanium implants using different surgical techniques. *Clin. Oral Impl. Res.* 25, 2014, 487–492
doi: 10.1111/clr.12180

To improve primary implant stability in patients with low-density type 4 bone, which is found in the posterior maxilla, in patients with osteoporosis, and after irradiation therapy, lateral compression of host bone has been successfully utilized in oral implantology (Summers 1994; Friberg et al. 1999, 2001). In the above mentioned studies, lateral compression was achieved by placement of an implant into a bone cavity considerably smaller in diameter as compared to the implant diameter itself, resulting in higher insertion torque, which is in turn an indicator of higher primary stability (Shalabi et al. 2006; Tabassum et al. 2009). However, doubts are raised if this improved stability remains in time, because the induced high stresses during implant placement may also provoke peri-implant bone resorption. In the view of above mentioned, the aim of the present study is to investigate the effect of the surgical technique on primary (mechanical) as well as secondary (biological) stability of endosseous implants in low-density trabecular bone. For this purpose, an *in vivo* study was performed using three different surgical techniques selecting the iliac crest of the goat as an implantation model.

Material and methods

Dental implants

Forty-eight cylindrical-screw-type implants provided by Dyna[®] implants [dental engineering bone volume (BV); Bergen op Zoom, the Netherlands] were used. All implants were acid etched and measured 10 mm in length and 4.2 mm in diameter (Fig. 1a). Scanning electron microscopy (SEM) was used to characterize the surface topography of the implants.

Animal model and implantation procedure

Eight healthy mature (2–4 years of age) female Saane goats, weighing approximately

60 kg, were used in the present study. Approval of the Experimental Animal Ethical Committee was obtained (RU-DEC 2009-031) and national guidelines for the care and use of laboratory animals were followed. All surgical procedures were performed under general inhalation anaesthesia and sterile conditions. To reduce the risk of peri-operative infection, the goats received antibiotics pre-operatively (10 mg/kg Amoxicillin[®]; Centrafarm, Etten-leur, the Netherlands, intravenously), and post-operatively, at day 1 and day 3 (50 mg/kg intramuscularly Albipen[®] LA; Intervet BV, Boxmeer, the Netherlands). The analgesic Finadyne[®] (1 mg/kg, three times a day) was administered for 2 days after surgery. Before placement of the implants, the animals were immobilized in a ventral position. The pelvic area of goats was shaved and the anatomical structures were marked. First, a transverse skin incision was made, starting from the upper medial side of the iliac crest, subsequently continuing towards the anterior superior iliac spine in lateral direction on both sides of vertebral column (Schouten et al. 2010). Then, the incision was continued through the underlying tissue layers until the periosteum was reached. Subsequently, the periosteum was detached and elevated aside, exposing the iliac crest. With a gentle surgical technique, bone cavities were prepared on top of the iliac crest, using rotational speeds (800 rpm) and continuous internal cooling with sterile saline; a total of 48 implants were inserted. The distance between the holes was 4–5 mm. For the installation of the implants, three different approaches were used:

Approach 1: 5% undersized; a 5% undersized preparation procedure (according to the protocol of the manufacturer) was performed. Drilling was started using the pilot drill (2.0 mm diameter). Subsequently, the hole was widened by a consecutive series of standard drills, that is,

3.2, 3.6 and 4.0 mm in diameter provided by the manufacturer according to the type of implant. By installing a 4.2 mm-diameter implant in a 4.0-mm cavity, a reduction in diameter of about 5% was achieved.

Approach 2: 15% undersized; the same sequence of drills was used as for approach 1. However, the final drill (4.0 mm) was skipped. By installing a 4.2-mm diameter implant in a 3.6-mm cavity, a reduction in diameter of about 15% was achieved.

Approach 3: 25% undersized; the drilling was started using the pilot drill (2.0 mm diameter). Afterwards, the hole was widened by a 3.2-mm diameter drill. By installing a 4.2-mm diameter implant in a 3.2-mm cavity, a reduction in diameter of about 25% was achieved.

After implant placement, the soft tissues and the skin were closed in layers with resorbable sutures (Vicryl[®] 2.0; Ethicon Products, Amersfoort, the Netherlands). After 3 weeks of implantation, all eight goats were euthanized with an overdose of Nembutal[®] (Apharmo, Arnhem, the Netherlands). Hereafter, the iliac wings were harvested and excess tissue was removed. By using a diamond blade saw, the iliac crests were divided into smaller pieces. As a result, each specimen contained just one implant with surrounding bone.

In each iliac crest wing, the three test implants were installed according to the experimental design of Latin squares. In each animal, the order of placement was the same for the left wing as the right wing. The retrieved samples from the right iliac crest ($n = 24$) were used for histological analysis. The samples collected from the left iliac wing ($n = 24$) were mechanically tested.

Mechanical testing

Insertion torque measurements (force required for the installation of the implant i.e. an indicator of primary stability): during installation, the peak insertion torque was measured for all implants ($n = 16$) using a Digital[®] torque gauge instrument (MARK-10 Corporation, New York, NY, USA).

Removal torque measurements (force required to remove the implant from bone i.e. an indicator of secondary stability): to prepare the specimens for torque-out measurements, implants were embedded in a mould and placed on a support jig. As this jig can be adapted in all directions, a direction of removal torque was chosen longitudinal on




Fig. 1. (a) Dyna[®] implants with acid-etched surface topography (dental engineering bone volume; Bergen op zoom, The Netherlands). (b) Surface of implant visualized by Scanning electron microscopy showing a uniformly rough surface (magnification 3000 \times).

the implant. Subsequently, to each implant, a controlled, a gradually increasing, rotational force (displacement; 0.5 mm/min) was applied until loosening of the implant. The peak force at implant loosening was measured as removal torque.

Micro-CT analysis

Before histological processing, the specimens were utilized for Micro-CT analysis. The bone blocks containing one implant each (dehydrated in 70% ethanol) were wrapped in Parafilm® (SERVA Electrophoresis GmbH, Heidelberg Germany) to prevent drying during scanning. The specimens were placed on the sample holder of the microCT imaging system with long axis of implant perpendicular to the x-ray beam (Skyscan 1072, Kontich, Belgium). Then all samples were scanned at high resolution of 37.14 µm/pixel. Subsequently a cone beam reconstruction was performed on all the projected files by using Nrecon VI.4 software (Skyscan 1072). Finally, 3D creator software was used to reconstruct a 3D model of the implant and the surrounding bone. In addition, bone volume fraction (bone volume/total volume) of the iliac crests was also determined.

Histological preparations

For histological and histomorphometrical analysis, 24 implants were used ($n = 8$ for each surgical approach). All specimens for histology were fixed in formaldehyde 4%, dehydrated in a graded series of ethanol (70–100%) and embedded (non-decalcified) in methylmethacrylate (MMA). After polymerization of the MMA, thin (15–20 µm) non-decalcified sections were prepared with a modified diamond blade sawing microtome technique (Van der Lubbe' et al. 1988). According to the routine procedure (Caulier et al. 1997), three sections were prepared through the middle part of the implant, but at least 300 µm apart in distance. The sections were made in a longitudinal direction parallel to the long axis of the implant and subsequently stained using methylene blue and basic fuchsin.

Histological and histomorphometrical evaluation

To evaluate the bone response around the implants, histological as well as histomorphometrical analyses were performed using a light microscope (Leica Microsystems AG, Wetzlar, Germany). Image analysis software (Leica qwin pro-image, V 2.5, Weizlar, Germany) was used for histomorphometrical evaluation. Quantitative measurements were

performed on both sides of the histological image for three different sections of each implant. The average of these six measurements was used for statistical analysis. The quantitative parameter calculated was %BV around the implant for three different peri-implant zones: the inner zone (0–500 µm), the middle zone (500–1000 µm) and the outer zone (1000–1500 µm) (Fig. 2).

Statistical analysis

All data were expressed as a mean \pm SD. Two-tailed *t*-test was conducted to compare the difference between groups. Statistical analysis of %BV for different zones (inner, middle and outer zone) was performed at three different levels: (i) with respect to surgical technique (difference between groups); (ii) comparison within group for inner, middle and outer zone; and (iii) overall data ($n = 8$; as for each goat average value of inner, middle or outer zone was calculated irrespective of the surgical technique). All calculations were performed using the SPSS software (IBM® SPSS 17.0; IBM NL, Amsterdam, the Netherlands). The statistical significant level was set at 5% ($P < 0.05$).

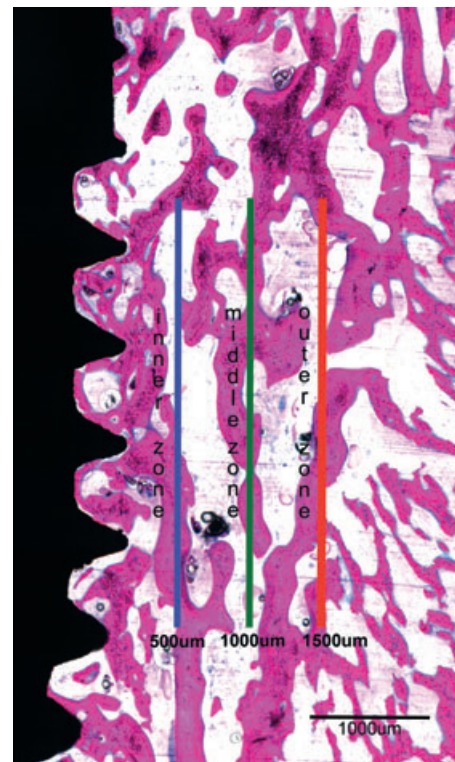


Fig. 2. Histological section of a 25% undersized implant (magnification 2.5 \times) showing three different zones for histomorphometrical analysis, that is, inner zone (0–500 µm); middle zone (500–1000 µm); and outer zone (1000–1500 µm).

Results

Surface characterization

Scanning electron microscopy showed a uniformly roughened surface topography (Fig. 1b).

Experimental animals

All animals remained healthy after the surgery. At sacrifice no signs of inflammation or other adverse tissue reactions could be observed. Of the 48 installed implants, five implants were damaged during analysis and had to be excluded from further evaluation (Table 1). To date, no correlation was observed between lost implants and any particular surgical technique.

Mechanical testing

The scatterplots of data of insertion and removal torque measurements are shown in Figs 3 and 4, respectively. The insertion torque values measured were for approach 1 (5% undersized) 26.5 ± 5.8 Ncm; for approach 2 (15% undersized) 31.4 ± 8.5 Ncm; and for approach 3 (25% undersized) 30.9 ± 10.3 cm. Statistically significant difference could only be observed between 5% and 15% undersized surgical technique ($P = 0.046$). However, as quite a number of statistical tests were performed, thereby increasing the chance of a false-positive result effect, this value, for example $P = 0.046$, was considered as an artefact of the multiple testing.

As such, no statistically significant difference could be observed between the surgical approaches. The removal torque values were for approach 1 (5% undersized) 44.39 ± 16.1 Ncm; for approach 2 (15% undersized) 39.4 ± 14 Ncm; and for approach 3 (25% undersized) 35.03 ± 13.7 Ncm. Statistical analysis showed no significant difference between various applied techniques. Although the removal torque values were higher for 5%, 15% and 25% undersized surgical technique, as compared to insertion torque values, no statistically significant difference could be observed for three applied surgical techniques. Overall data, irrespective of the applied surgical technique, demonstrated a significant difference between insertion and removal torque values ($P < 0.001$) after 3 weeks of implantation.

Histology

Light microscopic examination of all the implants demonstrated no signs of inflammation. The iliac crest of the goat mainly consisted of trabecular bone. No intervening

Table 1. Number of the implants placed, retrieved and used for different analysis

Surgical technique	Total implants placed/ insertion torque	Implant used for removal torque	Implant used for histomorphometrical analysis
5% undersized	16	7*	8
15% undersized	16	7†	7‡
25% undersized	16	7†	7‡

*During explantation, one implant could not be retrieved.
 †Two implants were placed near to the distal edge of the iliac crest and failed to osseointegrate as they became loose during removal of the cover screws.
 ‡Two implants were damaged during histological preparation.

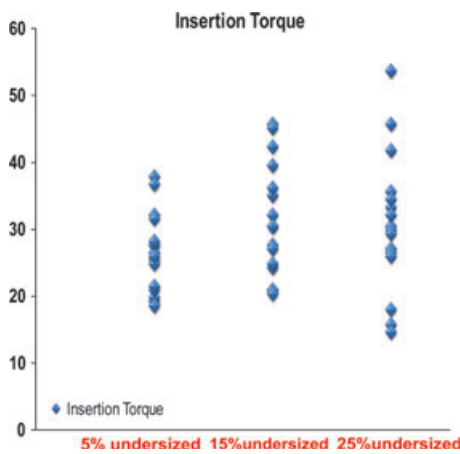


Fig. 3. Scatterplot of data showing insertion torque values as obtained with various surgical techniques.

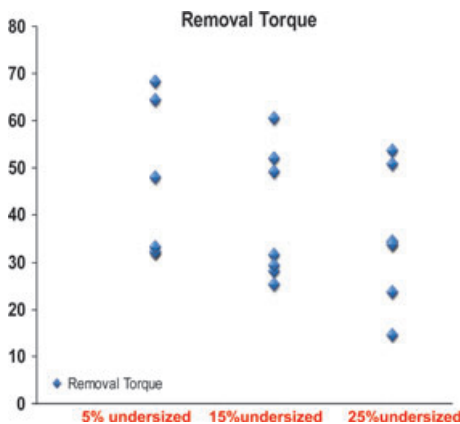


Fig. 4. Scatterplot of data showing removal torque values as obtained with various surgical techniques.

fibrous tissue layer was observed between any implant and the surrounding bone. All sections showed that the apical parts of all implants were in contact with the surrounding bone. In case of *approach 1* (5% undersized), histological examination demonstrated that most of the screw vents were completely filled with newly formed bone. The bone was in close contact at the top of the screw threads, and bone in-growth was visible from the top of the screw threads into the screw vents. For *approach 2* (15% undersized), the implants showed a bone healing

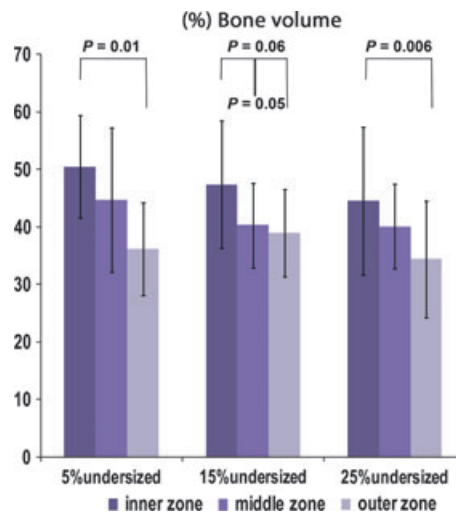


Fig. 5. The mean \pm SD of histomorphometrical data calculated for implants placed with 5% undersized, 15% undersized and 25% undersized after 3 weeks of implantation. A significantly higher %bone volume in the inner zone as compared to the outer zone was calculated for implants installed with the 5%, 15% and 25% undersized technique.

response almost similar as observed for the implants installed with the 5% undersized technique. In case of *approach 3* (25% undersized), examination demonstrated that the trabecular bone was only partially in contact with the implant surface. The in-growth of newly formed bone into the screw threads was less abundant as compared to the implants inserted with the 5% undersized or 15% undersized surgical technique.

Histomorphometrical analysis

Mean data \pm SD of the %BV are depicted in Figs 5 and 6. No significant difference regarding %BV between the three surgical techniques for inner, middle and outer zone was observed. However, regardless of the applied surgical technique, overall data (Fig. 6) showed significantly higher %BV for the inner zone as compared to the middle and outer zone ($P = 0.029$ and $P = 0.001$), respectively. Specified for the 5%, 15% and 25% undersized surgical technique, the %BV was significantly higher for the inner zone ($P = 0.01$, $P = 0.06$ and $P = 0.006$,

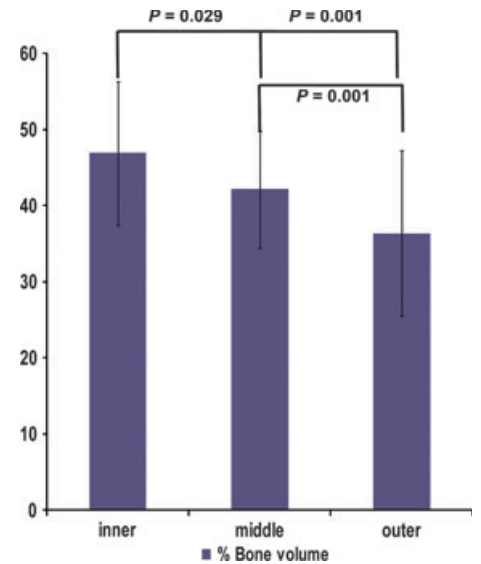


Fig. 6. The mean \pm SD of overall %bone volume data: a significantly higher %bone volume in inner zone as compared to middle and outer zone was calculated.

respectively) as compared to the outer zone (Fig. 5). In contrast, for all individual surgical techniques, no significant difference could be observed between inner and middle zone or middle and outer zone.

Micro-CT analysis

Bone volume fraction (bone volume/total volume) calculated for the iliac crest bone was $20.8 \pm 6.1\%$. An example of a micro-CT 3D image of the implant with surrounding bone is shown in Fig. 7. The iliac crest of goat demonstrated a well-defined trabecular bone structure. At the upper crest, no cortical layer could be observed. The bone was in close contact with the implant especially between the screw threads. The 3D model showed that the drilling procedure was accurate, as the apical part of the implant was in contact with the surrounding bone.

Discussion

The present study focused on the effect of the surgical technique on the primary and secondary stability of titanium implants. Primary stability can be achieved at the time of surgical placement due to mechanical engagement between implant and host bone. Secondary stability is achieved in time by new bone formation. Both primary and secondary stability can be displayed as bone-implant interface strength (Atsumi et al. 2007).

The undersized surgical technique (choosing a smaller drill diameter than implant diameter) is particularly recommended for low-density bone (Friberg et al. 1999; Ostman

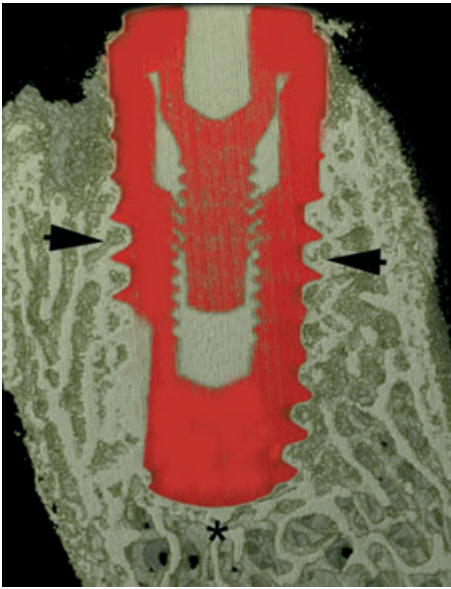


Fig. 7. Micro-CT 3D image of implant installed with 15% undersized surgical technique. The iliac crest of goat demonstrated a well-defined trabecular bone structure; however, at upper crest, no cortical layer could be observed. The bone was in close contact with the implant especially between the screw threads (see arrows). The apical part of the implant was also in intimate contact with the surrounding bone (see asterix).

et al. 2005), therefore, in the present study, the iliac crest of goat was used as an implantation model (Schouten et al. 2010; Tabassum et al. 2011a,b). This iliac crest mainly consists of porous trabecular bone with almost no cortical layer, showing a bone volume fraction of $20.8 \pm 6.1\%$ (Tabassum et al. 2010a,b). This is significantly lower than reported, for example, for the femoral condyle that is 57.4% (Schouten et al. 2010). In addition, as nowadays, immediate and early loading protocols are often employed in clinical practice, the present study focused on early secondary implant stability, that is, 3 weeks after implant placement.

Data from the present study exhibited no significant difference between 5%, 15% or 25% undersized surgical technique. Also in a previously performed animal study, in which tapered screw-type implants were inserted into the femoral condyles of goats, authors could not observe any significant difference in terms of insertion torque values for etched implants placed with different surgical techniques, that is, press-fit (71 ± 29 Ncm), undersized (85 ± 39 Ncm) and osteotome (72 ± 17 Ncm) technique (Shalabi et al. 2007). The results of present study are not in line with our previously performed *in vitro* study (Tabassum et al. 2010b), in which tapered screw-type implants were bicortically placed in the cadaver iliac wing of a goat

using two different surgical techniques (press-fit and undersized technique). Implants installed with the undersized surgical technique showed higher primary stability (40.8 ± 9.23 Ncm) as compared to implants inserted with the press-fit technique (30.1 ± 5.33 Ncm). However, it should be noticed that there is a difference in micro-architecture of bone used in the two studies. By placing the implants into the upper border of the iliac crest, as is executed in the present study, solely the effect of low-density trabecular bone is investigated, as no cortical layer could be observed at the upper border of the iliac crest. When the implants are installed into the iliac wing (perpendicular on the iliac crest), thus perforating both the outer and inner cortical layer of the wing, also the effect of the cortical layers can be judged (Tabassum et al. 2010b). The dominant role of cortical thickness in relation to primary implant stability has been already demonstrated in various other studies (Miyamoto et al. 2005; Rozé et al. 2009; Tabassum et al. 2010a). As such, higher implant stability can be ensured by engaging the implant screw threads into the cortical layer (Sennerby et al. 1992; Tabassum et al. 2010a).

Removal torque value is an indirect measurement for both primary and secondary stability of implants, as it determines the force required to destroy bone-implant interface contact (Buser et al. 1998). In the present study, no significant difference in removal torque measurements could be observed between all three groups. These results are in concurrence with a previously performed study, where no significant difference could be observed regarding removal torque values for etched implants placed with three different surgical techniques after 12 weeks of implantation using femoral condyle of goat as an implantation model (Shalabi et al. 2007). In addition, Halldin and coworkers have demonstrated that the effect of the undersizing is largely dependent on the type of bone. In trabecular bone of femur of rabbits, no statistically significant difference was found, regarding removal torque values, between undersized and press-fit implants. However, in cortical tibial bone, significant difference between two approaches was observed (Halldin et al. 2011).

As in our previous *in vivo* study, a higher percentage bone-implant contact (%BIC) for the 5% and 15% undersized technique was scored, as compared to the 25% undersized technique (Tabassum et al. 2011a), it may be hypothesized that 3 weeks after implantation, implant stability is not solely related to

Bone-Implant Contact (%BIC). With other words, at 3 weeks after implantation, a higher %BIC does not contribute to higher implant stability, probably due to the low calcification rate of the newly formed bone at the implant-bone interface.

In the present study, overall data exhibited significantly higher removal torque values as compared to the insertion torque values. Raghavendra et al. (2005) suggested an inverse relationship between primary and secondary stability; after implant installation, the primary stability is eventually replaced by the secondary stability. The time frame for this changeover depends on the animal model (Raghavendra et al. 2005). Based at the higher removal torque values, as compared to the insertion torque values, it can be assumed that in the present study, transition from mechanical to biological stability was already predominantly achieved after 3 weeks of implantation.

New bone formation around endosseous implants takes place in two directions: (i) distance osteogenesis, in which new bone formation occurs on the surface of the old bone present in the peri-implant area; (ii) contact osteogenesis, in which new bone forms directly in contact with the implant surface after colonization of the implant surface by bone-forming cells (Davies 2003). Therefore, to investigate the effect of undersizing, the peri-implant area was divided into three different zones, that is, the inner zone (0–500 μm) representing the area of contact osteogenesis, the middle zone (500–1000 μm) in which distance osteogenesis occurs and the outer zone (1000–1500 μm) represents the existing host bone (Schouten et al. 2009). Histomorphometric measurements in this study revealed that for all three surgical techniques, the %BV was higher in the inner zone as compared to the outer zone. This can be explained by (i) condensation of the host bone in immediate vicinity of the implant, as also by (ii) the phenomenon of translocated host bone particles, as they are tossed off due to friction between implant and host bone and subsequently pushed in between the trabecular voids and screw threads during implant placement (Dhore et al. 2008; Tabassum et al. 2011b, 2010b). It was hypothesized that the 25% undersized surgical technique should improve the %BV around the implant, especially in inner zone, as compared to 5% or 15% undersized technique. Surprisingly, no statistical significant difference was found between all applied surgical techniques regarding the %BV for the inner, middle or outer zones (Fig. 4), thus

showing that undersizing itself does not improve the peri-implant bone volume.

In conclusion, at 3 weeks after implantation, no additional beneficial effect of the 25% undersized surgical technique was seen, as compared to the 5% or 15% undersized surgical technique with respect to both torque-out value and peri-implant bone volume. As in our previous study, it was convincingly

shown that reduction in the diameter of the last drill more than 15% compared to the implant diameter resulted in less bone-to-implant contact; for the 25% undersized technique, a lower torque-out value was expected. Therefore, more research is needed to congregate sufficient biological data to support the use of undersized drilling procedures in the clinical practice.

Acknowledgements: The author would like to acknowledge the Higher Education Commission of Pakistan for their financial support and the Dyna® dental engineering BV (Bergen op zoom, The Netherlands) for providing implants for the present study. The author would also like to thank Vincent cuipers for Micro-CT analysis and Muhammad Ali for statistical analysis.

References

- Albrektsson, T. (2001) Is surgical skill more important for clinical success than changes in implant hardware? *Clinical Implant Dentistry and Related Research* **3**: 174–175.
- Atsumi, M., Park, S.H. & Wang, H.L. (2007) Methods used to assess implant stability: current status. *International Journal of Oral Maxillofacial Implants* **22**: 743–754.
- Berglundh, T., Abrahamsson, I., Lang, N.P. & Lindhe, J. (2003) De novo alveolar bone formation adjacent to endosseous implants. *Clinical Oral Implants Research* **14**: 251–262.
- Buser, D., Nydegger, T., Hirt, H.P., Cochran, D.L. & Nolte, L.P. (1998) Removal torque values of titanium implants in the maxilla of miniature pigs. *International Journal of Oral Maxillofacial Implants* **13**: 611–619.
- Caulier, H., van der Waerden, J.P., Wolke, J.G., Kalk, W., Naert, I. & Jansen, J.A. (1997) A histological and histomorphometrical evaluation of the application of screw-designed calcium phosphate (Ca-P)-coated implants in the cancellous maxillary bone of the goat. *Journal of Biomedical Materials Research* **35**: 19–30.
- Davies, J.E. (2003) Understanding peri-implant endosseous healing. *Journal of Dental Education* **67**: 932–949.
- Dhore, C.R., Snel, S.J., Jacques, S.V., Naert, I.E., Frank Walboomers, X. & Jansen, J.A. (2008) In vitro osteogenic potential of bone debris resulting from placement of titanium screw-type implants. *Clinical Oral Implants Research* **19**: 606–611.
- Fini, M., Giavaresi, G., Torricelli, P., Borsari, V., Giardino, R., Nicolini, A. & Carpi, A. (2004) Osteoporosis and biomaterial osteointegration. *Biomedicine & Pharmacotherapy* **58**: 487–493.
- Friberg, B., Ekestubbe, A., Mellstrom, D. & Sennerby, L. (2001) Branemark implants and osteoporosis: a clinical exploratory study. *Clinical Oral Implants Research* **3**: 50–56.
- Friberg, B., Sennerby, L., Grondahl, K., Bergstrom, C., Back, T. & Lekholm, U. (1999) On cutting torque measurements during implant placement: a 3-year clinical prospective study. *Clinical Implant Dentistry and Related Research* **1**: 75–83.
- Halldin, A., Jimbo, R., Johansson, C.B., Wennerberg, A., Jacobsson, M., Albrektsson, T. & Hansson, S. (2011) The effect of static bone strain on implant stability and bone remodeling. *Bone* **49**: 783–789.
- de Jonge, L.T., Leeuwenburgh, S.C., Wolke, J.G. & Jansen, J.A. (2008) Organic-inorganic surface modifications for titanium implant surfaces. *Pharmaceutical Research* **10**: 2357–2369.
- Lee, J.H., Frias, V., Lee, K.W. & Wright, R.F. (2005) Effect of implant size and shape on implant success rates: a literature review. *Journal of Prosthetic Dentistry* **94**: 377–381.
- LioubavinaHack, N., Lang, N.P. & Karring, T. (2006) Significance of primary stability for osseointegration of dental implants. *Clinical Oral Implants Research* **17**: 244–250.
- Mavrogenis, A.F., Dimitriou, R., Parvizi, J. & Babis, G.C. (2009) Biology of implant osseointegration. *Journal of Musculoskeletal and Neuronal Interactions* **9**: 61–71.
- Miyamoto, I., Tsuboi, Y., Wada, E., Suwa, H. & Iizuka, T. (2005) Influence of cortical bone thickness and implant length on implant stability at the time of surgery: clinical, prospective, biomechanical, and imaging study. *Bone* **37**: 776–780.
- Ostman, P.O., Hellman, M. & Sennerby, L. (2005) Direct implant loading in the edentulous maxilla using a bone density-adapted surgical protocol and primary implant stability criteria for inclusion. *Clinical Implant Dentistry and Related Research* **7**: 60–69.
- O'Sullivan, D., Sennerby, L. & Meredith, N. (2000) Measurements comparing the initial stability of five designs of dental implants: a human cadaver study. *Clinical Implant Dentistry and Related Research* **2**: 85–92.
- O'Sullivan, D., Sennerby, L. & Meredith, N. (2004) Influence of implant taper on the primary and secondary stability of osseointegrated titanium implants. *Clinical Oral Implants Research* **15**: 474–480.
- Raghavendra, S., Wood, M.C. & Taylor, T.D. (2005) Early wound healing around endosseous implants: a review of the literature. *International Journal of Oral & Maxillofacial Implants* **20**: 425–431.
- Rozé, J., Babu, S., Saffarzadeh, A., Gayet-Delacroix, M., Hoomaert, A. & Layrolle, P. (2009) Correlating implant stability to bone structure. *Clinical Oral Implants Research* **20**: 1140–1145.
- Schouten, C., Meijer, G.J., van den Beucken, J.J., Spauwen, P.H. & Jansen, J.A. (2009) The quantitative assessment of peri-implant bone responses using histomorphometry and micro-computed tomography. *Biomaterials* **30**: 4539–4549.
- Schouten, C., Meijer, G.J., van den Beucken, J.J., Spauwen, P.H. & Jansen, J.A. (2010) A novel implantation model for the evaluation of the bone healing response to dental implants: the goat iliac crest. *Clinical Oral Implants Research* **21**: 414–423.
- Sennerby, L., Thomsen, P. & Ericson, L.E. (1992) A morphometric and biomechanical comparison of titanium implants inserted in rabbit cortical and cancellous bone. *International Journal of Oral & Maxillofacial Implants* **7**: 62–71.
- Sevimay, M., Turhan, F., Kilicarslan, M.A. & Eskitascioglu, G. (2005) Three-dimensional Finite element analysis of the effect of different bone quality on stress distribution in an implant-supported crown. *Journal of Prosthetic Dentistry* **93**: 227–234.
- Shalabi, M.M., Wolke, J.G., de Ruijter, A.J. & Jansen, J.A. (2007) A mechanical evaluation of implants placed with different surgical techniques into the trabecular bone of goats. *The Journal of Oral Implantology* **33**: 51–58.
- Shalabi, M.M., Wolke, J.G. & Jansen, J.A. (2006) The effects of implant surface roughness and surgical technique on implant fixation in an in vitro model. *Clinical Oral Implants Research* **17**: 172–178.
- Summers, R.B. (1994) A new concept in maxillary implant surgery: the osteotome technique. *Compendium* **15**: 152, 154–6, 158 passim; quiz 162.
- Tabassum, A., Meijer, G.J., Wolke, J.G. & Jansen, J.A. (2009) Influence of the surgical technique and surface roughness on the primary stability of an implant in artificial bone with a density equivalent to maxillary bone: a laboratory study. *Clinical Oral Implants Research* **20**: 327–332.
- Tabassum, A., Meijer, G.J., Wolke, J.G. & Jansen, J.A. (2010a) Influence of the surgical technique and surface roughness on the primary stability of an implant in artificial bone with different cortical thickness: a laboratory study. *Clinical Oral Implants Research* **21**: 213–220.
- Tabassum, A., Walboomers, X.F., Meijer, G.J. & Jansen, J.A. (2011a) Biological limits of the undersized surgical technique: a study in goats. *Clinical Oral Implants Research* **22**: 129–134.
- Tabassum, A., Walboomers, X.F., Wolke, J.G., Meijer, G.J. & Jansen, J.A. (2011b) The influence of surface roughness on the displacement of osteogenic bone particles during placement of titanium screw-type implants. *Clinical Implant Dentistry & Related Research* **13**: 269–278.
- Tabassum, A., Walboomers, X.F., Meijer, G.J. & Jansen, J.A. (2012) Translocation of autogenous bone particles to improve peri-implant osteogenesis. *Journal of Tissue Engineering and Regenerative Medicine* **6**: 519–527.
- Tabassum, A., Walboomers, F., Wolke, J.G., Meijer, G.J. & Jansen, J.A. (2010b) Bone particles and the undersized surgical technique. *Journal of Dental Research* **89**: 581–586.
- Van der Lubbe, H.B., Klein, C.P. & de Groot, K. (1988) A simple method for preparing thin (10 µm) histological sections of undecalcified plastic embedded bone with implants. *Stain Technology* **63**: 171–176.